

## Arteriovenous Malformation (AVM)

### basic level

#### Overview

An arteriovenous malformation (AVM) is an abnormal tangle of blood vessels in the brain or spine. Some AVMs have no specific symptoms and little or no risk to a one's life or health, while others cause severe and devastating effects when they bleed. Treatment options range from conservative watching to aggressive surgery, depending on the type, symptoms, and location of the AVM.

#### What is an arteriovenous malformation (AVM)?

Normally blood flows from the heart through large arteries to all areas of the body. The arteries branch and get smaller until they become a capillary, which is just a single cell thick. The capillary bed is where the blood exchanges oxygen and nutrients with the body tissues and picks up waste. The blood travels from the capillary bed back to the heart through veins. In an AVM, arteries connect directly to veins without a capillary bed in between (Fig. 1). This creates a problem called a *high-pressure shunt or fistula*. Veins are not able to handle the pressure of the blood coming directly from the arteries. The veins stretch and enlarge as they try to accept the extra blood. The weakened blood vessels can rupture and bleed and are also more likely to develop aneurysms. The surrounding normal tissues may be damaged as the AVM "steals" blood from those areas.

There are four types of AVMs:

- **Arteriovenous malformation** – abnormal tangle of blood vessels where arteries shunt directly into veins with no intervening capillary bed; high pressure.
- **Cavernoma** – abnormal cluster of enlarged capillaries with no significant feeding arteries or veins; low pressure.
- **Venous malformation** – abnormal cluster of enlarged veins resembling the spokes of a wheel with no feeding arteries; low pressure, rarely bleed and usually not treated.
- **Capillary telangiectasia** – abnormal capillaries with enlarged areas (similar to cavernoma); very low pressure.

AVMs can form anywhere there are arteries and veins and cause symptoms based on their location (see *Anatomy of the Brain, Anatomy of the Spine*).

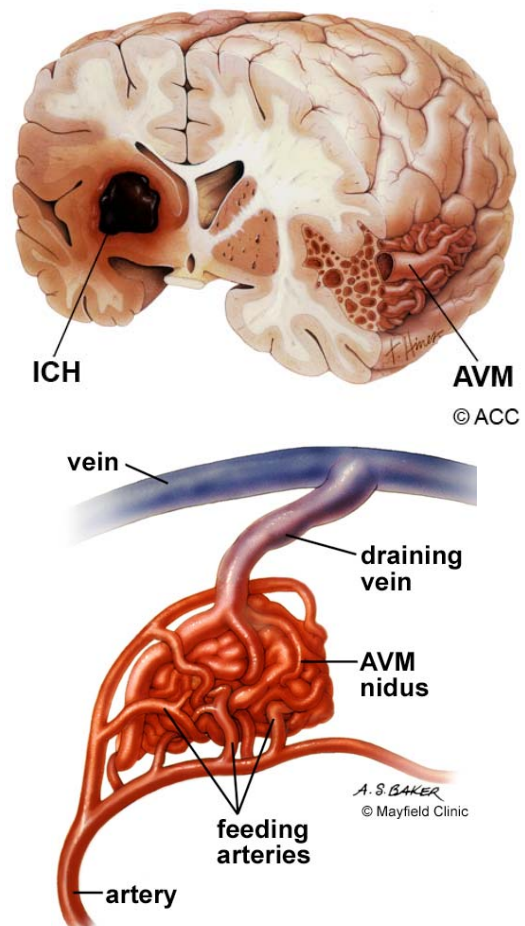


Figure 1. An AVM is a tangled bundle of blood vessels where arteries connect directly to veins with no capillary bed between. This creates a system of multiple feeding arteries, the tangle or nidus, and enlarged draining veins.

Brain AVMs can occur on the surface (also called cortical), deep (in the thalamus, basal ganglia, or brainstem), and within the dura (the tough protective covering of the brain). Dural AVMs are more accurately called arteriovenous fistulas (AVF). The veins of the brain drain into venous sinuses, blood filled areas located in the dura mater, before leaving the skull and traveling to the heart. In an AVF there is a direct connection between one or more arteries and veins or sinuses. Dural AV fistulas and carotid-cavernous fistulas (CCF) are the most common AVFs.

Spinal AVMs can occur on the surface (extramedullary) or within the spinal cord (intramedullary) and are classified into 4 types:

- Type 1 - (most common) is a dural arteriovenous fistula. They usually have a single arterial feeder and are thought to cause symptoms by venous hypertension.
- Type 2 – (also called glomus) is intramedullary and consists of a tightly compacted nidus over a short segment of the spinal cord.
- Type 3 – (also called juvenile) is an extensive AVM with abnormal vessels both intramedullary and extramedullary.
- Type 4 - are intradural extramedullary arteriovenous fistulas on the surface of the cord.

### Who is affected?

AVMs of the brain and spine are congenital (present at birth) and relatively rare. Approximately 300,000 (.14%) Americans have AVMs, but only 12% of those experience symptoms. They affect both men and women at about the same rate. They can occur at all ages, but most often cause symptoms between 20 and 40 years of age. AVMs account for about 2% of all hemorrhagic strokes each year.

### What are the symptoms?

The symptoms of AVMs vary depending on their type and location. While migraine-like headaches and seizures are general symptoms, most AVMs do not show symptoms (asymptomatic) until a bleed occurs. Common signs of brain AVMs are:

- Sudden onset of a severe headache, vomiting, stiff neck (described as "worst headache of my life")
- Seizures
- Migraine-like headaches
- Bruit: an abnormal swishing or ringing sound in the ear caused by blood pulsing through the AVM

Common signs of spinal AVMs are:

- Sudden, severe back pain
- Weakness in the legs or arms
- Paralysis

AVMs damage the brain or spinal cord in three ways:

1. AVMs can rupture and bleed into the brain—called an intracerebral hemorrhage (ICH), or it can bleed into the space between the brain and skull—called a subarachnoid hemorrhage (SAH). Small AVMs (less than 3 cm) are more likely to rupture than large ones. The bleeding can cause a stroke.
2. AVMs can grow large and create pressure against the surrounding brain, resulting in seizures and hydrocephalus. This is more common in large AVMs.
3. AVMs can reduce the amount of oxygen delivered to nearby tissues. Because the blood flows directly from the artery to the vein, cells that normally get oxygen from the capillaries begin to deteriorate.

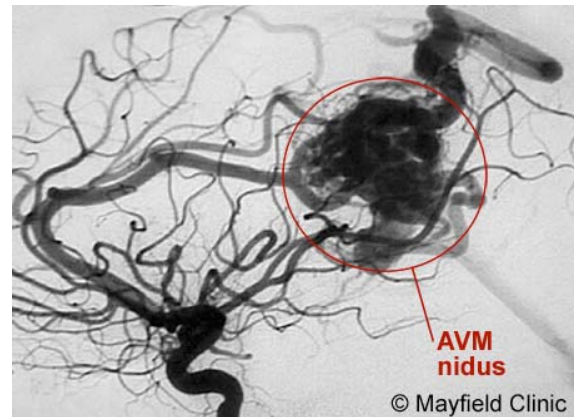


Figure 2. Angiogram depicts a large AVM in the parietal lobe of the brain. Feeding arteries lead to a tangled nidus (arrow) that shunt blood directly into a large draining vein (arrowhead).

### What is the risk of rupture?

The risk of AVM bleeding is 2 to 3% per year. Death from the first hemorrhage is between 10 to 30%. Once a hemorrhage has occurred, the AVM is 9 times more likely to bleed again during the first year.

Patients often want to know their *lifetime* risk of bleeding if they're weighing the risks and benefits of having surgery. Using the following formula one can calculate their risk [1]:

**Lifetime risk (%) = 105-patient's age**

For example, a 25-year-old man has an 80% lifetime risk of bleeding (at least once). Many factors affect this percentage, including *where* the AVM is located and what *type* of AVM it is. It's best to talk to your doctor about your own individual risk.

### How is a diagnosis made?

Whether you or a loved one was brought to the emergency room with a ruptured AVM or are considering treatment options for an unruptured AVM, the doctors will learn as much about your symptoms, current and previous medical problems, current medications, family history, and perform a physical exam. Diagnostic tests are used to help determine the AVM's location, size, type, and involvement with other structures.

**Computerized Tomography (CT) scan** is a noninvasive X-ray to view the anatomical structures within the brain to detect blood in or around the brain. A newer technology called CT angiography involves the injection of contrast into the blood stream to view the arteries of the brain. This type of test provides the best pictures of blood vessels through angiography and soft tissues through CT.

**Magnetic Resonance Angiography (MRA)** is a noninvasive test, which uses a magnetic field and radio-frequency waves to give a detailed view of the soft tissues of your brain. An MRA (Magnetic Resonance Angiogram) is the same non-invasive study, except it is also an angiogram, which means it also examines the blood vessels, as well as the structures of the brain.

**Angiogram** is an invasive procedure, where a catheter is inserted into an artery and passed through the blood vessels to the brain. Once the catheter is in place, a contrast dye is injected into the bloodstream and the X-ray images are taken (Fig. 2).

### What treatments are available?

Surgery, endovascular therapy, and radiosurgery can be used alone or in combination to treat an AVM. Endovascular embolization is often performed before surgery to reduce the AVM size and risk of operative bleeding. Radiosurgery or embolization may be used after surgery to treat any remaining portions of the AVM. Your neurosurgeon will discuss with you all the options and recommend a treatment that is best for your individual case.

#### Observation

If there have been no previous hemorrhages, the doctor may decide to observe the patient, which may include using anticonvulsants to prevent seizures and medication to lower blood pressure.

#### Radiosurgery

Radiosurgery aims a precisely focused beam of radiation at the abnormal vessels. The procedure takes several hours of preparation and one hour to deliver the radiation. The patient goes home the same day. After six months to two years, the vessels gradually close off and are replaced by scar tissue. The advantage of this treatment is no incision and the procedure is painless. The disadvantages are that it works best with smaller AVMs and may take a long time to show effect (during which time risk of hemorrhage exists).

In a recent long-term study done at Mayo Clinic, 73% of patients had excellent or good outcomes after radiosurgery and were protected from the risk of future bleeding [2].

#### Endovascular Therapy

Endovascular treatment uses small catheters inserted into your blood vessels to deliver glue or other obstructive materials into the AVM so that blood no longer flows through the malformation (Fig. 3). It is performed in the angiography suites of the Radiology Department by a Neuro Interventionalist. The procedure is performed under general anesthesia. A small incision is made in the groin and a catheter is inserted into an artery then passed through the blood vessels to the feeding

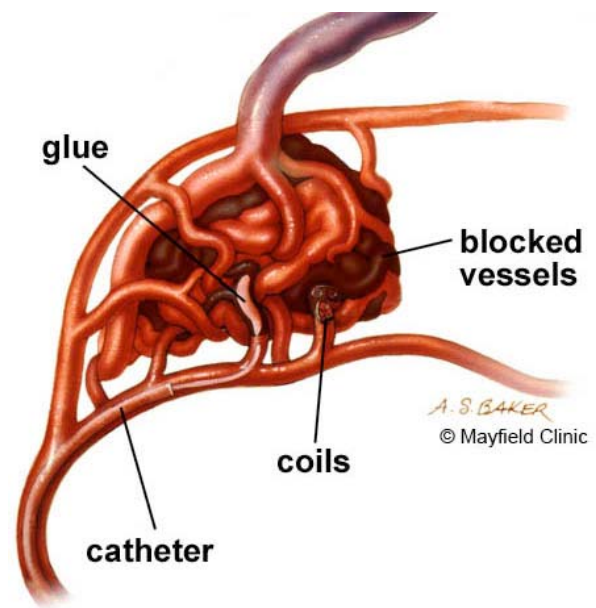


Figure 3. During an endovascular procedure, a microcatheter is inserted into the arteries feeding the AVM. Materials, such as glue or coils, are inserted into the abnormal arteries to block the flow of blood into the AVM nidus.

arteries of the AVM. Occluding material, either coil or acrylic glue, is passed through the catheter into the AVM. The procedure time can vary, and the patient remains in the hospital several days for observation. The advantage of this treatment is it's less invasive than surgery and can be used to treat deep or inoperable AVMs. Disadvantages include risk of embolic stroke from the catheter and rebleeding since the AVM is not completely obliterated. Multiple treatments may be necessary.

#### Surgery

Using general anesthesia, a surgical opening is made in the skull, called a craniotomy. The brain is gently retracted so that the AVM may be located. Using a variety of techniques such as laser and electrocautery, the AVM is shrunk and dissected from normal brain tissue. The length of stay in the hospital varies between 5 to 7 days with some short-term rehabilitation. The type of craniotomy performed depends on the size and location of the AVM. The option of surgery also depends on the general health of the patient. The advantage of surgical treatment is that a cure is immediate if all the AVM is removed. Disadvantages include risk of bleeding, damage to nearby brain tissue, and stroke to other areas of the brain once removed.

## Clinical trials

Clinical trials are research studies in which new treatments—drugs, diagnostics, procedures, vaccines, and other therapies—are tested in people to see if they are safe and effective. Research is always being conducted to improve the standard of medical care and explore new drug and surgical treatments. You can find information about current clinical investigations, including their eligibility, protocol, and participating locations on the web: the National Institutes of Health (NIH), [www.clinicaltrials.gov](http://www.clinicaltrials.gov), sponsors many trials; private industry and pharmaceutical companies also sponsor trials. [www.centerwatch.com](http://www.centerwatch.com)

## Current Studies

For more information about clinical trials by our doctors, go to:  
[www.mayfieldclinic.com/ClinicalTrials.htm](http://www.mayfieldclinic.com/ClinicalTrials.htm)

## Sources & Links

If you have more questions, please contact the Mayfield Clinic at 800-325-7787. Contact the AVM Support Group of Toronto, Canada at 415-603-5880.

## Sources

1. Ogilvy CS, et al.: Recommendations for the Management of Intracranial Arteriovenous Malformations. *Stroke* 32: 1458-71, 2001.
2. Pollock BE, Gorman DA, Coffey RJ: Patient Outcomes after Arteriovenous Malformation Radiosurgical Management: Results Based on a 5- to 14-year Follow-up Study. *Neurosurgery* 52: 1291-7, 2003.

## Links

National Institute of Neurological Disorders & Stroke  
[ninds.nih.gov/health\\_and\\_medical/pubs/arteriovenous.htm](http://ninds.nih.gov/health_and_medical/pubs/arteriovenous.htm)

Intracranial Arteriovenous Malformation  
[www.emedicine.com/med/topic3469.htm](http://www.emedicine.com/med/topic3469.htm)

Spinal Malformation  
[www.emedicine.com/med/topic2896.htm](http://www.emedicine.com/med/topic2896.htm)

Aneurysm & AVM Support  
[www.westga.edu/~wmaples](http://www.westga.edu/~wmaples)

## Glossary

**aneurysm:** a bulge or weakening of an arterial wall.  
**arteriovenous fistula:** an abnormal passage or opening between an artery and a vein.  
**arteriovenous malformation:** abnormality of blood vessels where arteries shunt directly into veins with no intervening capillary bed.  
**capillary telangiectasia:** abnormal collection of enlarged capillaries.  
**cavernous malformation:** abnormal collection of blood vessels with no well defined feeding arteries or draining veins.  
**craniotomy:** surgical opening in the skull.  
**dura mater:** a tough, fibrous, protective covering of the brain and spinal cord.  
**embolization:** blockage of a blood vessel so blood can no longer flow through it.  
**endovascular:** occurring within the blood vessels.  
**hemorrhage:** bleeding in the brain, which may cause a stroke.  
**hydrocephalus:** swelling in the brain due to a blockage of cerebrospinal fluid.  
**nidus:** the central part of an AVM.  
**occlusion:** the process of closing.  
**shunt:** diversion of fluid (blood, CSF).  
**subarachnoid hemorrhage:** bleeding in the space surrounding the brain; may cause a stroke.  
**venous malformation:** abnormal tangle of veins.  
**venous sinus:** a blood filled channel that lacks normal vessel walls.

updated > 4.2009

reviewed by > Mario Zuccarello, MD  
Nancy McMahon, RN



This information is not intended to replace the medical advice of your doctor or health care provider. For more information about our editorial policies and disclaimer of liability visit [www.mayfieldclinic.com/policies.htm](http://www.mayfieldclinic.com/policies.htm), or write to attn: Tom Rosenberger, Mayfield Clinic & Spine Institute, 506 Oak Street, Cincinnati, OH 45219 513.221.1100 • 800.325.7787

© Mayfield Clinic 2009. All rights reserved.